Eur. J. Stomatol. Oral Facial Surg. (2026) 03:02
DOI: https://10.61318/ejsofs.v3i2.23

The European Journal of Stomatology, Oral and Facial Surgery

https://ejsofs.com

Case-report

Article history
Received: 30 January 2025
Accepted: 2 August 2026
Published: 9 October 2026

Keywords:
Calcium Sulfate, Dental Impression Technique, Dental Materials, Foreign Bodies, Maxilla

*Author for correspondence. Email: dr.francisco.g.gouveia@gmail.com

Accidental Use of Plaster in a Dental Impression Leading to Metal Tray Retention: A Case Report

Francisco Gouveia,[*,1,2] Catarina Alexandra Rodrigues Araújo,[3] Leonor Cruz e Silva,[1] Sara Fontes,[1] and Francisco Salvado[1,2]

[1]Serviço de Estomatologia. Unidade Local de Saúde de Santa Maria. Lisboa. Portugal.
[2]Faculdade de Medicina. Universidade de Lisboa. Lisboa. Portugal.
[3]Bloco Operatório Central II. Unidade Local de Saúde de Santa Maria. Lisboa. Portugal.

Abstract

Dental impression materials are used for capturing the characteristics of intraoral structures and producing hard and soft tissue models for dental prostheses, orthodontic appliances, and other clinical purposes. Preparation of these materials must strictly follow the manufacturer's instructions in order to preserve their properties and ensure a predictable clinical outcome. A 20-year-old man presented to the Emergency Department of Stomatology of a tertiary hospital with an inability to remove a metal impression tray retained in the maxilla for approximately 15 hours. The incident occurred during a home impression procedure in which dental plaster was mistakenly used instead of alginate, owing to their similar appearance, and mixed to a thicker than recommended consistency. Clinical examination revealed a closed metal tray embedded in the upper arch containing hardened plaster. The tray was sectioned bilaterally using a diamond turbine bur, and the hardened plaster was subsequently removed with a handpiece and carbide bur. No injury to the teeth or oral mucosa was observed, and follow-up examinations at one and five months confirmed intact oral tissues with preserved tooth sensitivity.

This case illustrates how a closed, non-perforated tray filled with a rigid, non-elastic material can become mechanically locked over dental undercuts, precluding its removal. It underlines the importance of adherence to the manufacturer's instructions, professional supervision, and controlled clinical environments during dental impression procedures. To the authors' knowledge, this is the first reported case of this specific complication.

Highlights

- Accidental use of dental plaster instead of alginate led to a metal impression tray becoming mechanically locked in the maxilla.
- Retention resulted from mechanical interlocking of the rigid, set plaster over dental undercuts, not from a thermal or allergic reaction.
- The tray was safely released by controlled bilateral sectioning with a turbine and diamond bur, without injury to the teeth or oral mucosa.
- Tooth sensitivity and temporomandibular joint function remained normal at 5-month follow-up.
- Home dental impression procedures performed with incorrect materials pose a preventable but under-recognised risk of tray retention, and this is, to the authors' knowledge, the first reported case of this specific complication.

European Journal of Stomatology, Oral & Facial Surgery

© 2026 The Authors. Published by SPECO-AMEP — Sociedade Portuguesa de Estomatologia e Cirurgia Orofacial – Associação dos Médicos Estomatologistas Portugueses.
This is an open-access article distributed under the terms of the Creative Commons Attribution-NonCommercial-NoDerivatives 4.0 International licence (CC BY-NC-ND 4.0).

How to cite this article:
Gouveia F, Araújo C, Cruz e Silva L, Fontes S & Salvado F. (2026). Accidental use of plaster in a dental impression leading to metal tray retention: a case report. The European Journal of Stomatology, Oral and Facial Surgery 03 (02): e23. DOI: https://10.61318/ejsofs.v3i2.23

1. Introduction

Dental plaster (calcium sulfate hemihydrate) sets through an exothermic hydration reaction into calcium sulfate dihydrate, a rigid, brittle mass with no elastic recovery.[1] Alginate, by contrast, is an elastic, hydrophilic hydrocolloid that can be inserted and withdrawn from undercut areas without fracturing, which is why it is the material of choice — rather than gypsum products — for preliminary, orthodontic, and study-model impressions, despite its lower dimensional stability and detail reproduction.[2]

Complications of dental impression procedures, although uncommon, are well documented and include aspiration or ingestion of impression material or tray fragments,[3–5] thermal injury,[6] and allergic reactions,[7] and, more rarely, retention of the tray itself due to mechanical locking over anatomical or dental undercuts. Because these events are more likely to happen when procedures are performed outside a supervised clinical setting, impression-taking should be reserved for trained professionals working in an environment equipped to manage such complications and ensure patient comfort.

2. Case Report

A 20-year-old dental student presented at the Emergency Department of Stomatology, Hospital Santa Maria, with an inability to remove a metal tray that had been retained in his maxilla for approximately 15 hours (Fig. 1). The patient reported that he had been practising an at-home dental impression and had mistakenly used dental plaster instead of alginate, owing to the similar appearance of the two materials. The specific type of dental plaster used could not be determined, and its exact powder-to-water ratio was not recorded.

2.1. Clinical Examination

Examination revealed a standard, closed metal tray lodged in the maxilla and filled with hardened plaster (Figs. 1A, 1B, 1C). A small ulcer was noted on the palatal mucosa adjacent to the posterior border of the tray. No radiographic imaging (periapical, panoramic, or CBCT) had been obtained at presentation, as the tray remained in place within the patient's mouth. Temporomandibular joint assessment, including palpation, range of mandibular opening, and pain on function, was unremarkable.

2.2. Procedure

The procedure was performed without anaesthesia or analgesia, with the patient conscious throughout. The airway was protected by continuous suction for the duration of the procedure. The metal tray was sectioned bilaterally at paramedian points using a diamond turbine bur (Fig. 1D), with the handpiece's own water spray used for cooling, after which the hardened plaster was carefully removed with a handpiece and carbide bur (Fig. 1E, 1F).

No additional injury to the teeth or oral mucosa was observed during or after the procedure. Sensitivity of the upper-arch teeth was preserved immediately after the procedure and at follow-up visits at one and five months (Fig. 2 shows the immediate and 5-month examinations), and temporomandibular joint findings remained unremarkable at both follow-up visits. The palatal ulcer was managed with surveillance alone, without antibiotic prophylaxis, and healed by secondary intention.

The patient provided consent for publication of this case and the accompanying clinical images. Institutional ethics committee approval was not applicable to this case report.

3. Discussion

To the authors' knowledge, this is the first reported case of impression-tray retention resulting from the inadvertent use of dental plaster. The central finding of this case is mechanical rather than chemical or thermal: a closed (non-perforated) tray filled with a rigid, non-elastic material becomes locked over the undercuts created by the crowns and interproximal contacts of the dental arch. Because set dental plaster, unlike alginate, has no elastic recovery, the tray–material complex cannot be withdrawn along its path of insertion without either fracturing the set material *in situ* or applying forces that risk damaging the teeth and supporting structures. This mechanism — rather than an exothermic reaction — best explains why the tray could not be removed intact and why removal required sectioning of the tray itself.

No thermal injury was observed, and the temporomandibular joint was clinically assessed (palpation, range of mandibular opening, and pain on function) at presentation and at both follow-up visits, with normal findings throughout. Thermal injury and temporomandibular dysfunction, described in other clinical contexts,[6, 8–10] did not apply to the present case.

4. Conclusion

Beyond the largely self-evident lesson that impression procedures should not be attempted by untrained individuals outside a supervised setting, the principal contribution of this report is the description of a technique for safely releasing a mechanically locked tray using controlled bilateral sectioning with a turbine and diamond bur, followed by careful removal of the hardened material with a handpiece and carbide bur, which avoided injury to the teeth and oral mucosa and preserved tooth sensitivity at five months. Recognising undercut-related mechanical locking, rather than a chemical or thermal injury, as the operative mechanism may help guide management of similar presentations.

This case reinforces the importance of adherence to the manufacturer's instructions when preparing impression materials, of restricting impression-taking to trained professionals working in controlled environments, and of accessible training to prevent similar occurrences.

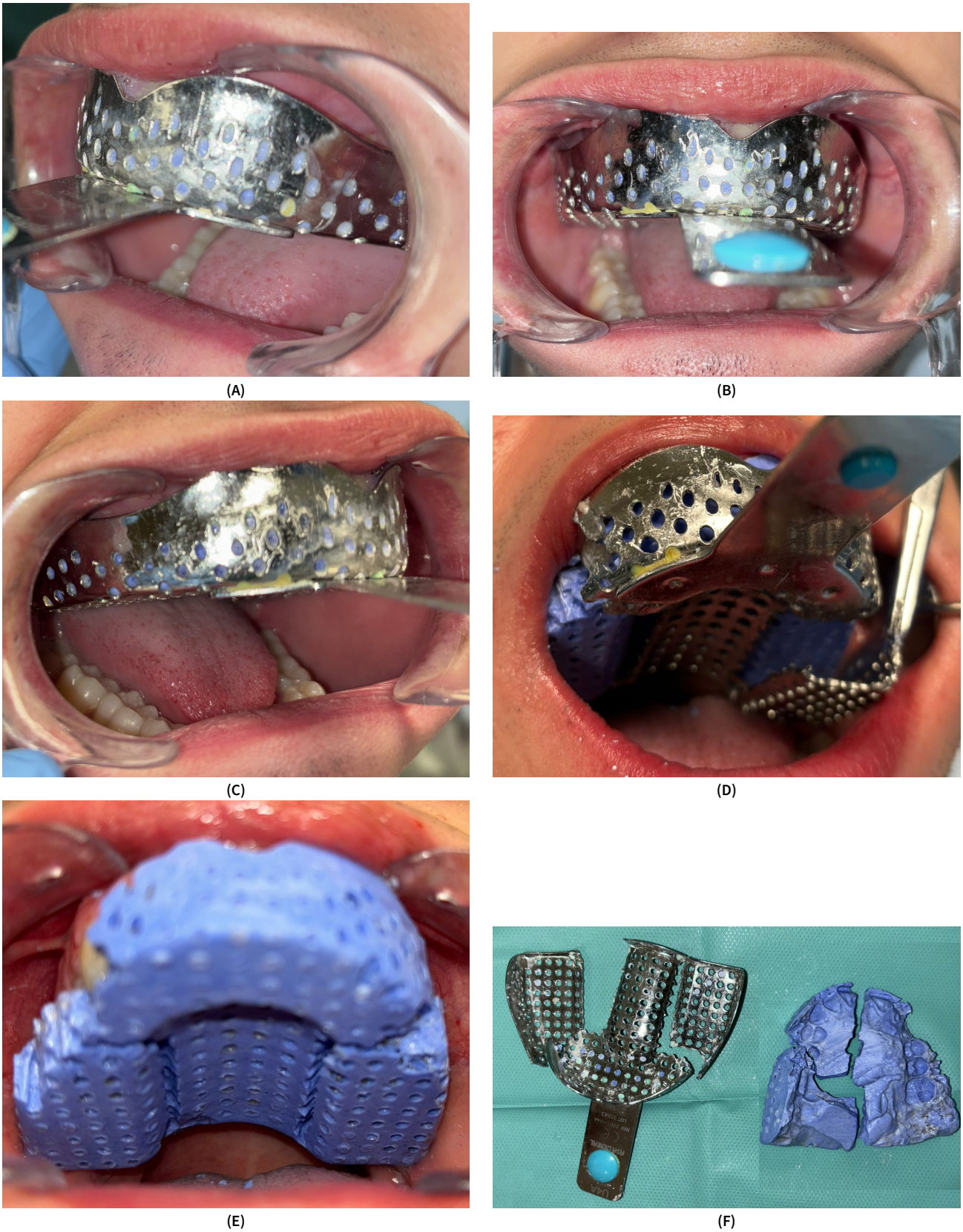

Figure 1. (A) Closed metal tray retained in the maxilla. (B,C) Intraoral views of the retained tray with hardened plaster. (D) Bilateral sectioning of the tray using a turbine with a diamond spherical bur. (E) Hardened plaster following removal of the sectioned tray. (F) Sectioned tray and removed plaster block ex vivo.



Figure 2. Assessment of upper-arch tooth sensitivity: panels A–C, immediately after the procedure; panels D–F, at the 5-month follow-up.

Acknowledgments: During the preparation of this work, the authors used the artificial intelligence tool Claude (Anthropic) in order to correct and improve the language and readability of the manuscript. After using this tool, the authors reviewed and edited the content as needed and take full responsibility for the content of the published article.

Funding: This research received no specific grant from any funding agency in the public, commercial, or not-for-profit sectors.

Competing Interests: The authors declare that they have no competing interests.

Notes

References

[1] Ricketts, D. *Advanced operative dentistry: a practical approach*; Churchill Livingstone, Elsevier: Edinburgh, 2011.

[2] Punj, A.; Bompolaki, D.; Garaicoa, J. Dental impression materials and techniques. *Dent Clin North Am* **2017**, *61*, 779–796. https://doi.org/10.1016/j.cden.2017.06.004.

[3] Hou, R.; Zhou, H.; Hu, K.; Ding, Y.; Yang, X.; Xu, G.; Xue, P.; Shan, C.; Jia, S.; Ma, Y. Thorough documentation of the accidental aspiration and ingestion of foreign objects during dental procedures is necessary: review and analysis of 617 cases. *Head Face Med* **2016**, *12*, 23. https://doi.org/10.1186/s13005-016-0120-2.

[4] Negrete, J.R.; Carrillo, M.D.; Molina, G.A.; Ayala, O.A.V.; Flores, D.; Castillo, D. Do not open wide; accidentally swallowed dental mould causing bowel obstruction. A case report. *J Surg Case Rep* **2022**, *2022*, rjac384. https://doi.org/10.1093/jscr/rjac384.

[5] Bateman, G.; Saha, S. Aspiration of dental impression material — a case report. *Dent Update* **2017**, *44*, 986–987.

[6] Chauhan, V.S.; Mir, M.A. Plaster burn: challenge to plastic surgeon. *World J Plast Surg* **2018**, *7*, 226–230.

[7] Syed, M.; Chopra, R.; Sachdev, V. Allergic reactions to dental materials — a systematic review. *J Clin Diagn Res* **2015**, *9*, ZE04–ZE09. https://doi.org/10.7860/JCDR/2015/15640.6589.

[8] Jain, M.J.; Mavani, K. Lethal necrotizing fasciitis triggered by plaster: case report and review of literature. *J Orthop Case Rep* **2016**, *6*, 73–75. https://doi.org/10.13107/jocr.2250-0685.640.

[9] Rai, A.; Mittal, M.; Mittal, S. Accidental ingestion of plaster of Paris causing thermal injury of the oesophagus and stomach in a toddler. *Indian Pediatr Case Rep* **2023**, *3*, 234–236. https://doi.org/10.4103/ipcares.ipcares_133_23.

[10] Yegane, R.A.; Bashashati, M.; Bashtar, R.; Ahmadi, M. Gastrointestinal obstruction due to plaster

ingestion: a case report. *BMC Surg* **2006**, *6*, 4. https://doi.org/10.1186/1471-2482-6-4.